

# CHANGES IN THE CONTRACTILE APPARATUS OF THE ISOLATED RAT HEART ASSOCIATED WITH CALCIUM ION DEFICIENCY

L. N. Belov

UDC 612.172.5.014.46:546.41

Retrograde coronary perfusion of the isolated rat heart with calcium-deficient Hanks's solution leads to cardiac arrest. Microscopic examination revealed destruction of the intercalated disks, followed by segmentation of the myocardium. The dissociated segments contracted sharply but the myofibrils in them remained in a definite order. After further perfusion with complete Hanks's solution the contractile activity of the isolated heart was restored, but the segmentation of the myocardium did not disappear.

The inability of the myocardium to contract in the absence of calcium ions while preserving its bio-electrical activity is well-known [6, 8]. More recent investigations have demonstrated the complex role of calcium ions in the initiation of excitation, the coupling of excitation with contraction, and the regulation of permeability of the cell membrane. Calcium ions are essential for the functioning of several enzyme systems, including the ATPase system, and for the maintenance of contacts between the muscle cells of the myocardium.

Attempts have been made to demonstrate the importance of disturbances of the calcium balance in the development of myocardial injury. However, changes observed in the myocardium during perfusion of the isolated heart with calcium-free solutions have been interpreted quite differently. Gradually developing deaggregation of the myofibrils of the muscle cells with the formation of an optically empty sarcolemmal sheath has been described [9]. This phenomenon, known as "myofibrosis," was attributed to the need for calcium ions for morphological integration of the myofibrils. After other observations on the myocardium when perfused under similar conditions severe injuries (contractures) to the muscle cells were described [7]. These changes were regarded as the result of a disturbance of cell adhesion.

Since contractural changes and myocytolysis have been shown to be clearly distinguishable types of injury to heart muscle cells [2-5], it is interesting to discover what type of changes are produced in the myocardium by calcium ion deficiency.

## EXPERIMENTAL METHOD

The isolated hearts from 50 male albino rats weighing 120-150 g were treated by retrograde coronary perfusion with oxygenated Hanks's solution at 37°C. Besides complete Hanks's solution containing 1.2 mmole  $\text{Ca}^{++}$  per liter, solutions containing 0.6, 0.12, 0.06, 0.04, and 0.03 mmole  $\text{Ca}^{++}$  per liter and calcium-free solutions were used. The hearts were perfused for 5 min with complete Hanks's solution and then with one of the  $\text{Ca}^{++}$ -deficient solutions for 5 min to 2 h. Some of the isolated hearts perfused with the  $\text{Ca}^{++}$ -deficient solution were again perfused with the complete Hanks's solution for 1 h.

The methods of preparation of the material for microscopic investigation and the changes arising in the myocardium during perfusion with complete Hanks's solution for 5 min to 2 h were described previously [1].

---

Laboratory of Pathomorphology, Clinical Division, Institute of Cytology and Genetics, Siberian Division, Academy of Sciences of the USSR, Novosibirsk. (Presented by Academician of the Academy of Medical Sciences of the USSR A. P. Avtsyn.) Translated from *Byulleten' Éksperimental'noi Biologii i Meditsiny*, Vol. 76, No. 11, pp. 109-111, November, 1973. Original article submitted February 12, 1973.

© 1974 Consultants Bureau, a division of Plenum Publishing Corporation, 227 West 17th Street, New York, N. Y. 10011. No part of this publication may be reproduced, stored in a retrieval system, or transmitted, in any form or by any means, electronic, mechanical, photocopying, microfilming, recording or otherwise, without written permission of the publisher. A copy of this article is available from the publisher for \$15.00.

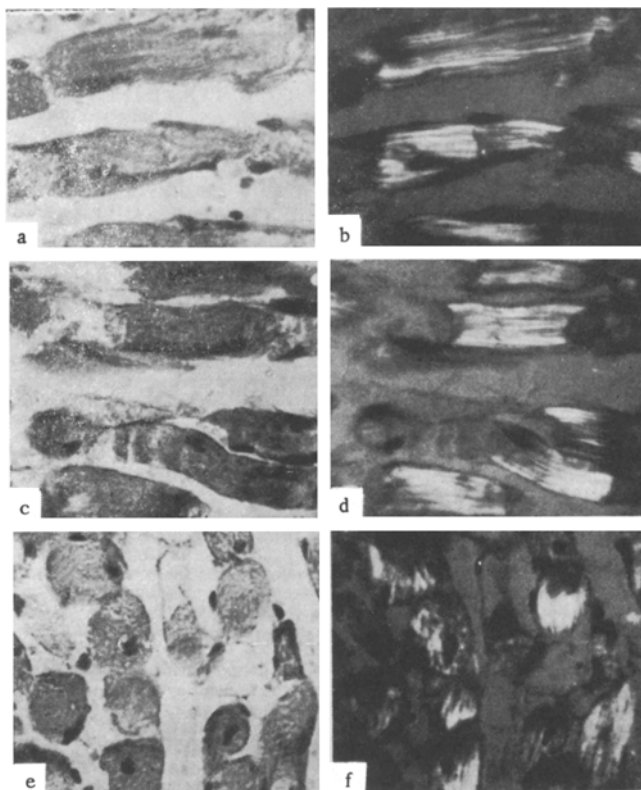


Fig. 1. Area of myocardium from a heart perfused with calcium-free Hanks's solution: a, b) commencing destruction of intercalated disks; c, d) dissociated segments in sarcolemmal sheath; e, f) contracturally changed muscle segments. PAS reaction combined with staining with colloidal iron and hematoxylin, 630 $\times$ ; a, c, e) photographed in ordinary light; b, d, f) photographed in polarized light.

#### EXPERIMENTAL RESULTS

The course of development of the distinctive changes arising in the contractile apparatus of the myocardium during perfusion of the isolated heart with  $\text{Ca}^{++}$ -deficient solutions can be studied in detail by histological and, in particular, by polarization microscopic methods. These changes consisted of swelling of the intercalated disks with deaggregation of the myofibrils in areas lying next to the disks (Fig. 1a, b). Muscle cells previously joined together into a fiber became separated from one another, their myofibrils contracted sharply, their cross striation disappeared, and it was replaced by continuous anisotropy. These contracturally changed segments, preserving the cylindrical shape of the myocardial cell, each with one or two slightly pycnotic nuclei, were located in a well-preserved sarcolemmal sheath (Fig. 1c, d). An isotropic globular substance, varying in amount, could be observed between the segments inside the sarcolemmal sheath. If the perfusion continued for long enough, the orderly pattern just described was disturbed. The segments contracted still more, lost their connection with one another through the sarcolemma, and became rounded in shape (Fig. 1e, f). Despite such profound changes in the muscle cells, the myofibrils in them underwent neither complete lysis nor complete deaggregation but preserved a definite orderliness, as demonstrated by their anisotropy.

To give rise to the above-mentioned changes in the contractile apparatus of the muscle cells it was sufficient to perfuse for 15 min with Hanks's solution containing 0.04 mmole  $\text{Ca}^{++}$  or less per liter. Raising the  $\text{Ca}^{++}$  concentration in the solution to 0.12 mmole/liter led to the development of changes such as these only after perfusion for 2 h. In this calcium concentration the contractile activity of the myocardium ceased however, after perfusion for 3-5 min. The segmentation of the myocardium described above spread to all parts of the heart if the isolated heart was perfused with solutions containing 0.03-0.06 mmole  $\text{Ca}^{++}$  per

liter or completely free from calcium for 1 h or more. Nevertheless, some of the muscle cells preserved their normal structure. In addition, in the severest forms of segmentation of the myocardium additional perfusion with complete Hanks's solution led to resumption of contractile activity.

The initial phases of the changes in the heart muscle cells during perfusion with solutions deficient in calcium ions are extremely similar to the histological picture of the myocardium observed after deliberate isolation of the muscle cells by homogenizing the myocardium or treating it with proteolytic enzymes and chelating agents. In conjunction with the other histological features of the changes in the myocardium in calcium ion deficiency, this similarity agrees well with existing data [7] and suggests that the key factor in the development of the myocardial injuries described above is a change in the properties of the intercalated disks followed by dissociation of the muscle cells. Perfusion with solutions with calcium deficiency evidently gives rise to irreversible destruction of the intercalated disks, for equally extensive zones of segmentation are observed during perfusion with calcium-deficient solutions for 1 h and with complete Hanks's solution for 1 h after preliminary perfusion for 15 min with the calcium-free solution. The essential fact is that the dissociated heart muscle cells undergo further gross changes, with karyorrhexis of the nuclei in them.

#### LITERATURE CITED

1. L. N. Belov and L. I. Khaustova, *Byull. Éksperim. Biol. i Med.*, No. 8, 110 (1971).
2. L. A. Semenov and Yu. G. Tsellarius, *Kardiologiya*, No. 1, 112 (1971).
3. Yu. G. Tsellarius, *Arkh. Pat.*, No. 1, 34 (1967).
4. Yu. G. Tsellarius and L. A. Semenova, *Izvest. Sibirsk. Otdel. Akad. Nauk SSSR*, No. 4, Ser. Biol. Med. Nauk, No. 1, 125 (1965).
5. Yu. G. Tsellarius and L. A. Semenova, *Histopathology of Focal Metabolic Injuries to the Myocardium* [in Russian], Novosibirsk (1972).
6. G. R. Mines, *J. Physiol. (London)*, 46, 188 (1913).
7. A. R. Muir, *J. Anat. (London)*, 102, 148 (1968).
8. S. Ringer, *J. Physiol. (London)*, 4, 29 (1883).
9. D. L. Weiss, B. Surawicz, and I. Rubinstein, *Am. J. Path.*, 48, 655 (1966).